

## JOURNAL OF CLINICAL AND DIAGNOSTIC RESEARCH

How to cite this article:

INDUMATHI S, SUDHA S, HANNAH SUGIRTHABAI RAJILA R. AORTIC ARCH AND VARIATIONS IN ITS BRANCHING PATTERN. Journal of Clinical and Diagnostic Research [serial online] 2010 October [cited: 2010 October 16 ]; 4:3134-3143.

Available from

[http://www.jcdr.net/back\\_issues.asp?issn=0973-709x&year=2010 &month= August &volume=4&issue=4&page=xx &id=1080](http://www.jcdr.net/back_issues.asp?issn=0973-709x&year=2010 &month= August &volume=4&issue=4&page=xx &id=1080)

## ORIGINAL ARTICLE

# Aortic Arch And Variations In Its Branching Pattern

INDUMATHI S\*, SUDHA S\*\*, HANNAH SUGIRTHABAI RAJILA R\*\*

### ABSTRACT

**Background:** The relationship of the arch of the aorta and its branches are embryologically determined and are found to be highly variable. This makes the arch of the aorta more vulnerable to injury during the surgical manipulation of the heart, lungs and the great vessels. The arch anomalies produce tracheo-oesophageal constriction, which accounts for 1%-2% of all congenital heart defects. The present study was undertaken to study the variations in the branching pattern of the arch of the aorta in the South Indian population and their surgical applications.

**Aim:** An extensive analysis of the arch of the aorta, which is surgically important, was done under the following headings such as origin, whether it is a left or right-sided aortic arch, the normal branching pattern of the aortic arch and variations in the branching pattern of the aortic arch.

**Methods:** The study material included 75 specimens consisting of 16 dissection room cadavers, 34 post - mortem en - bloc specimens and 25 patients who underwent angiograms. The study was carried out by using the conventional dissection method and angiograms. The radio graphical imaging of the arch of the aorta and its branches were obtained by the Angiogram, which combines the use of cineangiocardiology and aortography.

**Results:** The left aortic arch was found in 73 specimens (97.3%) and the right aortic arch in 2 specimens (2.67%). The normal branching pattern was present in 41 male specimens (89.1%) and in 24 female specimens (88.8%). The common origin for both the brachiocephalic and the left common carotid artery was present in 4 specimens (5.48%). 6.52% male specimens and 3.7% female specimens showed this variation. For the left vertebral artery arising from the aortic arch between the left common carotid and the left subclavian artery, 2.17% out of 46 male specimens and 7.4% out of 27 female specimens showed this variation. This type of variation was present in 4.1%. 73 specimens that had left aortic arch were taken and studied for right vertebral artery arising as fourth branch from the aortic arch. 1.36% showed this type of variation.

**Conclusion:** From the results of our present study, we conclude that no specific south Indian variation beyond the limits of average fluctuation was noted and also, the variations are not only clinically important, but are also clinically important to both the patient as well as the operating surgeons.

**Key Words:** Aortic arch, brachiocephalic artery, left common carotid artery, left subclavian artery, left vertebral artery, right subclavian artery.

\*Saveetha Medical College & Hospital, Saveetha University, Saveetha Nagar, Thandalam, Chennai - 602 105, Tamilnadu, INDIA; \*\*Stanley Medical College & Hospital, CHENNAI - 600 001.  
Corresponding Author:

INDUMATHI S,  
Assistant Professor, Department of Anatomy,  
Saveetha Medical College & Hospital,  
Saveetha University, Saveetha Nagar,  
Thandalam, CHENNAI - 602 105,

Tamilnadu, INDIA.

E-mail:indumathisivaji@gmail.com

## Introduction

The aortic arch normally lies within the superior mediastinum. The variations in the branching pattern of the aortic arch are mostly due to a developmental error [1],[2],[3]. Even in the normal aortic arch, the position of the origin of the brachiocephalic artery may assume surgical significance. Tracheal compression is caused when this artery arises in an anomalous position [4] and also, when it has a common origin with the left common carotid artery [5]. Arch anomalies are associated with congenital heart disease. The arch anomalies produce trachea-oesophageal constriction and obstruction [6],[7],[8]. The commonest anomaly of the aortic arch is the right subclavian artery that arises from the left side of the arch [9],[10],[11]. This artery may run either behind the oesophagus, between the oesophagus and the trachea, or in front of trachea [12]. In such cases, it can press upon the oesophagus and cause difficulty in swallowing, resulting in "dysphagia lusoria". In such a condition, the right laryngeal nerve does not become recurrent, but goes straight to supply the larynx. As a result, in thyroidectomy or in tracheostomy, the above unusual position of the nerve leads to a surgical hazard. The factors which determine the persistence and the dissolution of the aortic arch components are not completely known. The migration of the neural crest cells into the pharyngeal arches may play a significant role. The association of various arch anomalies such as the right aortic arch, an aberrant and isolated subclavian artery and the microdeletion of chromosome 22q11, imply a genetic component resulting in the derivation of at least some arch anomalies. The neural crest cells are also involved in the development of the conotruncus. The conotruncal anomalies which also occur in chromosome 22q11 deleted patients provide a further aetiological link for aortic arch anomalies. The critical aortic variations with fatal consequences were studied in the South African population [13]. The branching pattern was studied in people with Japanese ancestry who were born in Hawaii [14]. This study had emphasized the role of racial factors. This led to

several studies all over the world in an attempt to map the variations of the aortic arch. But the literature related to the Indian population is very limited. Hence, the present study was undertaken to study the variations in the branching pattern of the arch of the aorta in the South Indian population and their surgical applications.

In this study, the importance of the aortic arch, its variations, malformations and the branching pattern are stressed upon and described in detail. The anatomical, surgical and the roentgenological findings described in the literature, as well as from personal experience have been considered. Special attention has been paid to the variations in the branching pattern of the aortic arch.

## Materials And Methods:

The study was conducted in the Department of Anatomy, Stanley Medical College and Hospital, Chennai, Tamilnadu, India. An extensive analysis of the arch of the aorta, which is surgically important, was done under the following headings: -

- a) Origin
- b) Whether it is a left or right-sided aortic arch
- c) The normal branching pattern of the aortic arch
- d) Variations in the branching pattern of the aortic arch

The study was conducted in 75 specimens of both sexes by the routine dissection method and the angiographic method. This was done to correlate the findings of the study with the associated clinical conditions.

Sometimes, the anomalies may be totally asymptomatic and they may be fortuitously discovered. They have to be identified pre-operatively in order to modify the procedure of an eventual mediastinal surgery.

The study material consisted of

- a) 16 dissection room cadavers.
- b) 34 post - mortem en - bloc specimens.
- c) 25 patients who underwent angiograms.

**a) Dissection Room - Cadavers**

All the 16 cadavers (12 males and 4 females) had been embalmed with 10% formalin solution and immersed in tank solution containing 4% formalin solution for 3 months prior to dissection.

**b) Post-Mortem en-bloc Specimens-** 34 post-mortem en-bloc specimens were collected from the Department of Forensic Medicine, Stanley Medical College, Chennai. 34 (20 males and 14 females) specimens were studied by the conventional dissection method.

**The method of collection of the post - mortem en-bloc specimens**

The 34 post-mortem en-bloc specimens were collected from the Department of Forensic Medicine, Stanley Medical College, Chennai, from people who had died of road traffic or train traffic accidents.

Their autopsies had been carried out by the conventional "P" shaped incision from the hyoid bone to the pubic symphysis. The thorax was opened by cutting through the costochondral junctions, the lungs were removed and the heart, the arch of the aorta, its branches and the trachea were kept intact.

A transverse cut was made few centimeters distal to the tracheal bifurcation and a plane of dissection was obtained by lifting up the great vessels, the trachea and the oesophagus in the retro-oesophageal space.

At the level of the root of the neck, the medial ends of the clavicles were lifted up and the origins of the sternocleidomastoid muscles were separated. The 1<sup>st</sup> part of the subclavian artery was visualized.

The visceral package which consisted of the heart, the arch of the aorta, its branches, the oesophagus and the trachea were cut and were taken out carefully. The specimens were washed in water and saline and were then dissected and studied.

**c) Clinical Study**

25 patients (20 males and 5 females) who underwent angiograms in the Department of Cardio Thoracic Surgery, Stanley Medical College, Chennai, were included as the subjects for the study.

**METHODS OF STUDY**

- a) Conventional dissection method.
- b) Angiogram.

**Conventional dissection method**

*i. Dissection of Dissection room cadavers*  
The dissection was carried out according to the methodology prescribed by *Cunningham's manual*.

*ii) Dissection of the post -mortem en-bloc specimens*

The dissection and identification of the arch of the aorta and its branches were done by following the same steps as for the cadaveric specimens and the same parameters as mentioned above, were studied.

**Statistical analysis**

The statistical analysis was done by using SPSS statistical software. Student's t-tests, Chi-square test and one way ANOVA were employed to analyze the differences among the groups and to evaluate the statistical significance. The chosen level of significance was  $P < 0.05$ .

**RESULTS AND DISCUSSION:**

The origin, the side of the aortic arch, its branching pattern and the variations in the branching pattern of the aortic arch were studied by

1. The Conventional dissection method and
2. Clinical study by angiograms

Of the 75 (total) specimens, 28 male specimens and 22 female specimens (a total of 50) were studied by the routine dissection method. The specimens studied by angiograms included 20 males and 5 females (a total of 25).

The following observations were made during this study.

a) **Origin:**

In all the specimens which were studied, the arch of the aorta began as a continuation of the ascending aorta, behind the right second chondrosternal joint. The branches arose from the convexity of the aortic arch.

b) **Aortic arch** - whether left or right sided:

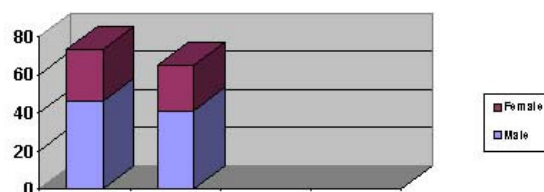
The 50-dissection specimens which were studied showed the left aortic arch. Among the 25-angiogram specimens, 2 showed the right aortic arch with the mirror image branching pattern. This observation was found in 2 male angiographic pictures who underwent cardiac catheterization .

Specimens Studied		Side of arch	
Sex	No.	Right	Left
Male	48	2	46
Female	27	-	27
Total	75	2	73

[Table/Fig. 1]: Right and left aortic arches

The left aortic arch was found in 73 specimens (97.3%) and the right aortic arch in 2 specimens (2.67%). The observations found in the present study are tabulated in [Table/Fig. 1] and [Table/Fig. 2]. Among the 48 male specimens studied, the aortic arch was on the left side in 46 males and on the right side in 2 males. In all the 27 female specimens, the left aortic arch was present.

Comparison of Normal Branching Pattern of Aortic Arch in both sexes



[Table/Fig 2] Comparison of normal branching pattern of aortic arch in both the sexes

c) **The Normal Branching Pattern of the Aortic Arch:**

The normal branching pattern of the Aortic arch is depicted in Table/Figure – 4.

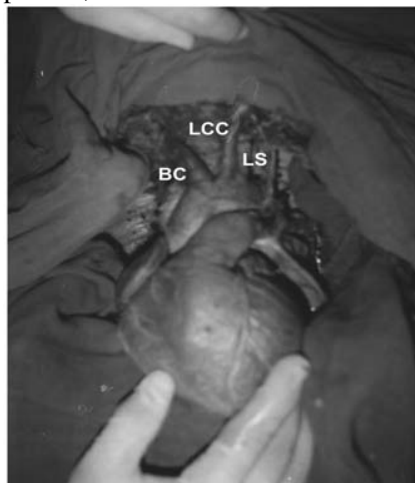
The normal branching pattern was studied in both the dissection and the angiogram specimens. In this study, 73 specimens which had the left aortic arch were taken into account. By the dissection method, 28 male specimens and 22 female specimens were studied. 25 male specimens and 19 female specimens had a normal branching pattern. The angiogram study consisted of 18 males and 5 females (a total of 23). 17 male and 5 female specimens showed the normal branching pattern. In this study, the normal branching pattern was present in 41 male specimens (89.1%) and in 24 female specimens (88.8%). The observations are tabulated in [Table/Fig. 3].

Specimens Studied		Normal Branching Pattern	
Sex	No.	No.	Percentage (%)
Male	46	41	89.1 %
Female	27	24	88.8%
Total	73	65	89%

[Table/Fig. 3] Normal branching pattern of aortic arch

Liechty and Shields reported that the normal branching pattern occurs in 70% of the specimens [1]. Anson gave an incidence of 65% and 86% was reported by Wright [2],[3]. An aortic arch study by arteriographic analysis, which was conducted by Satyapal K.S Singaram

in a South African population, recorded that 73% of the specimens had a normal branching pattern [13]. Martia L Nelson and Chad D Sparks showed that 94.3% of the specimens had a normal branching pattern, in a study conducted in men with Japanese ancestry who were born in Hawaii [14]. The 12<sup>th</sup> edition of Morris Human Anatomy states that 90% of the specimens have a standard branching pattern [15]. Hollinshead W.H. Anatomy for surgeons states that the normal branching pattern occurs in 50% of the Negroes and in 75% of the Whites [16]. A morphometric study on cadaveric aortic arches, conducted by Young Shin et.al in Korean adults, reported that 84% specimens had a normal branching pattern.[29]. A study conducted in Japanese cadavers by Toshiyuki Saito et.al showed that 83.3% of the specimens had a normal branching pattern.[31]. Gupta M.Sodhi reported 77% [32] and Soubhagya R.Nayak et.al reported that 91.4% of the specimens had a normal branching pattern [35]. Konstantinos .I.et.al, Berko Nekanel et.al, G.G.Jakanani, W.Adiar and Budhiraja Virendra, [38],[39],[40] and [41] reported that 83%, 65.9%, 74% and 95%, of the specimens had a normal branching pattern, respectively.

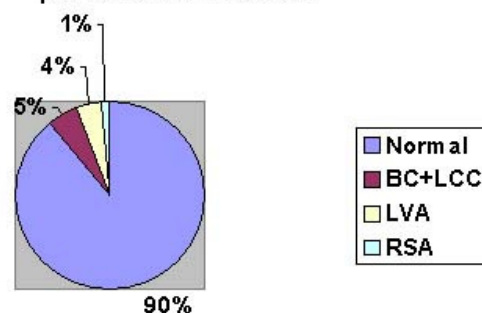


[Table/Fig. 4] Normal branching pattern of aortic arch

In the present study, it was seen that 89% of the specimens had a normal branching pattern. The results of the present study coincide with those of a previous study done by N.L. Wright [3] and the observations are shown in [Table/Fig. 4] and [Table/Fig. 5]. The importance of this

comparative study is that it shows that the present study's findings correlate with those of the past study.

**Normal and Variations of branching pattern of Aortic Arch**



[Table/Fig. 5] Normal and variations of branching pattern of aortic arch

Previous studies conducted in the Japanese population, the South African population, Negroes, Whites and Koreans showed marked differences in the incidence of the branching pattern of the aortic arch. This shows that racial differences may play a significant role in the branching pattern of the aortic arch.

**d) Variations in the Branching Pattern**

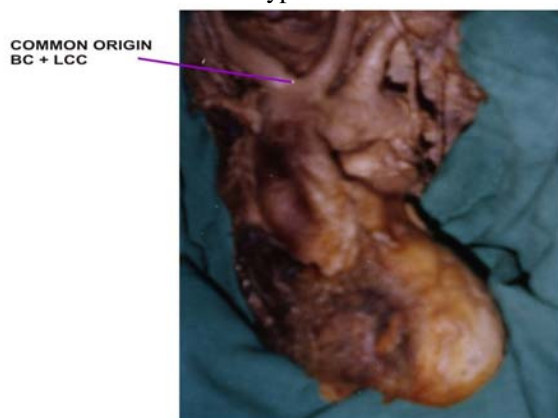
Four types of variations were observed during the study.

1. 4 specimens – had a common sharing for both the brachiocephalic artery and the left common carotid artery.
2. 3 specimens – had the left vertebral artery arising directly from the arch of the aorta between the left common carotid artery and the left subclavian artery.
3. 1 specimen – had the right subclavian artery as a 4<sup>th</sup> branch from the aortic arch.
4. 2 specimens – had the right aortic arch with a mirror image branching pattern.

**1. Common Sharing For both the Brachiocephalic and the Left**

**Common Carotid Arteries:**  
(Depicted in [Table/Fig 6])

In this study, specimens that had the left aortic arch were taken into account. From the dissection specimens (28+22), 2 male specimens out of 28 and 1 female specimen out of 22 showed this type of variation.



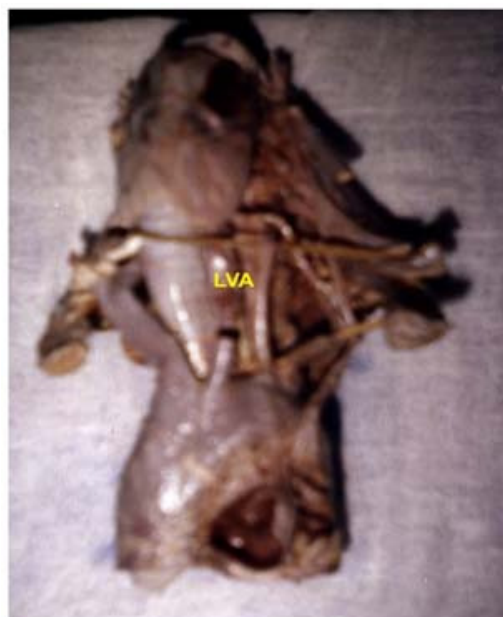[Table/Fig 6] Common sharing for brachiocephalic and left common carotid arteries

In the angiogram specimens (18+5), 1 male specimen out of 18 showed this type of variation. All 5 female specimens were normal. The observations are tabulated in [Table/Fig 7].

S.no	Methods	Sex	No.	Common Origin for BC + LCC
1	Dissection	Male	28	2
		Female	22	1
2	Angiogram	Male	18	1
		Female	5	0
3.	Total		73	4

[Table/Fig 7] Common origin for brachiocephalic artery and left common carotid artery

The common origin for both the brachiocephalic artery and the left common carotid artery were present in 3 male specimens (6.52%) and 1 female specimen (3.7%). This type of variation was encountered in 4 specimens (5.48%) [Table/Fig 5] and [Table/Fig. 7].



[Table/Fig 8] Left vertebral artery from the aortic arch

Liechty et al reported that 27% of the specimens had this type of variation [1]. Anson recorded that 27% and N .L Wright recorded that 7% of the specimens had this type of variation [2],[3]. The results of the present study on this variation coincide with those of the study by N.L. Wright [3]. A study conducted in the South African population by Satypal K S.Singaram showed that 3.4% of the specimens had a common stem for both the brachiocephalic and the left common carotid arteries [13]. Martia L.Nelson et al conducted a study on men of Japanese ancestry who were born in Hawaii and they recorded that 1.03% of the specimens had a common origin for both the brachiocephalic trunk and the left common carotid artery [14]. The 12<sup>th</sup> edition of Morris Human Anatomy states that 27% of the specimens have a common stem for the brachiocephalic artery and the left common carotid artery [15]. Hollinshead states that the incidence of this variation is 40% [16]. Piersol [17] stated that the common origin of the brachiocephalic and the left common carotid arteries is the commonest variation. Rutherford, Moss and Adams state that this type of variation is present in 10% of normal left arches [18], [20]. Toshiyuki Saito et.al recorded that 10.9% of the specimens had a common origin for both the brachiocephalic trunk and the left common

carotid artery, in a study conducted in Japanese cadavers.[31]. Gupta M.Sodhi.L reported that 12% of the specimens had a common origin for both the brachiocephalic trunk and the left common carotid artery [32]. Konstantinos.I et.al reported that 15% of the specimens had a common origin for both the brachiocephalic trunk and the left common carotid artery [38] . G.G.Jakanani and W.Adiar reported that 20% of the specimens had this type of variation [40].

**3. The Left vertebral artery arising from the aortic arch between the left common carotid artery and the left subclavian artery [Table/Fig 8]:**

In this study, 73 specimens (46+27) were studied. Out of 50 (28+22) dissection specimens, 28 male specimens did not show this type of variation. Among 22 female specimens, 2 specimens showed this type of variation.

In the angiogram specimens, out of 18 male specimens, 1 specimen showed this variation and all 5 female specimens were normal.

Out of 46 male specimens, 1 showed this type of variation (2.17%). Out of 27 female, 2 showed this type of variation (7.4%). This type of variation was present in 4.1% of the specimens [Table/Fig 5-9]

Liechty et.al conducted a study in 1000 specimens and recorded that 2.5% of the specimens had this variation (1).

Specimens Studied		Left V.A from arch of aorta	
Sex	No.	No.	Percentage
Male	46	1	2.17 %
Female	27	2	7.4%
Total	73	3	4.1%

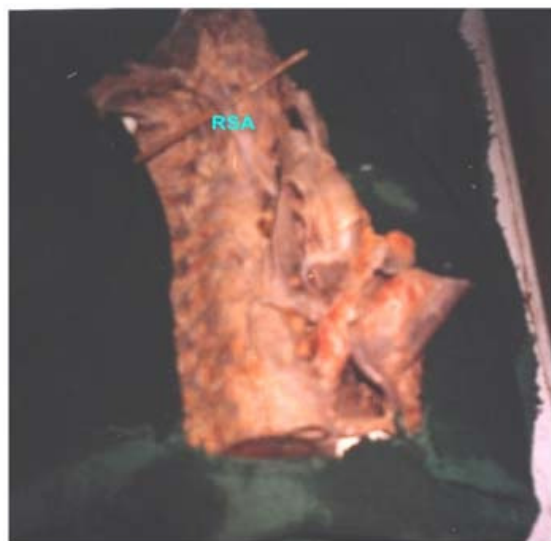**[Table/Fig 9] Variations in Left Vertebral Artery from Arch of Aorta**

Anson recorded that 2.5%, N.L Wright recorded that 8%, Satyapal K.S.Singaram recorded that 1.6% and Martia.L.Nelson et al recorded that

4.1% of the specimens had this variation [2], [3], [13], [14]. In the Morris Human Anatomy, it is stated that in 5% of the specimens, the left vertebral artery arises from the arch of the aorta [15]. Hollinshead and Rutherford state that in 5% of the specimens, the left vertebral artery arises directly from the aortic arch [16],[18]. This variation from the arch of aorta was reported by Brodie (19). Moss and Adams state that the incidence of this variation is 10% [20]. Lemkee et al reported a bilateral anomalous origin of the vertebral arteries from the the aortic arch [21]. Both arteries arose directly from the aortic arch between the left common carotid artery and the left subclavian artery. Sait,Albayram et al also reported this variation. [22]. The 39<sup>th</sup> edition (2004) of Gray’s Anatomy states that an analysis on 1000 aortic arches showed that 2.5% of the specimens had this variation [23]. Toshiyuki Saito et.al [31] recorded 4.3% and Gupta M.Sodhi.L [32] recorded that 4% of the specimens had this variation.Koh-ichi Yamaki et.al conducted a study on Japanese adults and reported that 5.8% of the specimens had this variation.[33]. Kazuchika Suzuki et.al recorded that 4.1%[34], The present study coincides with the variations studied by Martia.L.Nelson et al [14], as quoted in Hollinshead and Rutherford’s [16], [18] and with the study of Toshiyuki Saito et.al [31], Gupta M.Sodhi.L [32] and Suzuki et.al [34].

**4. The Right subclavian artery as the 4<sup>th</sup> branch from the aortic arch (Figure – 10):**





[Table/Fig 10] Right subclavian artery as 4<sup>th</sup> branch from the aortic arch

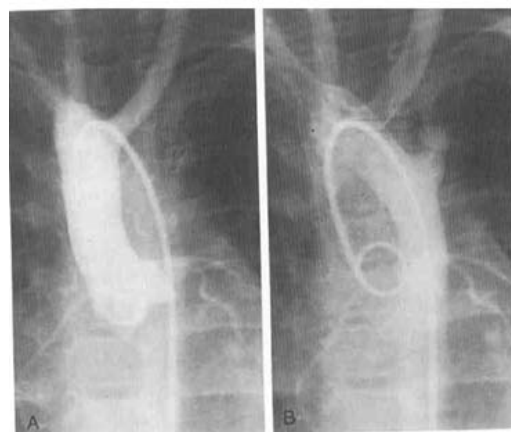
73 specimens that had the left aortic arch were taken and studied. In (28+22) 50 dissection specimens, only 1 male specimen showed the above said variation. The angiogram specimens 23(18+5) did not show this type of variation. Out of 73 specimens, 1.36% showed this type of variations. The right subclavian artery arising as a 4<sup>th</sup> branch from the arch of the aorta was retro-oesophageal in position. [Table/Fig 11], [Table/Fig 10].

Specimens Studied		Right subclavian Artery from arch of aorta	
Sex	No.	No.	Percentage
Male	46	1	2.17 %
Female	27	-	-
Total	73	3	1.361%

[Table/Fig 11] Right subclavian artery as 4<sup>th</sup> branch from the aortic arch

Liechty et.al reported this variant in 0.5% [1] and Bertolinia et al it in 2.4% of the specimens [4]. Few authors studied the relationship of the right subclavian artery arising directly from the arch of the aorta as the 4<sup>th</sup> branch and gave an incidence in 80% specimens of the aorta passing posterior to the oesophagus [11]. Moss and Adams reported an incidence of 0.9% [20] and Rutherford stated that this type of variation occurred in 1 % of the Negroes (18). An incidence of less than 1% and 1% about this

variant was reported by various authors [24], [25]. N.Z.Makhanye et.al, Toshiyuki Saito et.al, Soubhagya R.Nayak et.al, and Marios Loukas et.al reported this type of variation in 0.5%-1.0%, 0.2%, 1.6%, and 0.4-2% of the specimens respectively [30],[31],[35],[42]. The results of the present study coincide with those of most of the previous studies reported by many authors.



[Table/Fig. 12] Right aortic arch with mirror image branching

### THE RIGHT AORTIC ARCH WITH MIRROR IMAGE BRANCHING PATTERN:

In this condition, the aortic arch passes over the right main stem bronchus and joins a right – sided proximal descending aorta. The mirror image right arch has the first branch as a left brachiocephalic artery, which in turn divides into the left carotid and the left subclavian arteries. It has the second branch as the right carotid and the third branch as the right subclavian artery.

Rutherford stated that the incidence of the aortic arch with mirror image branching was 17% [18]. Moss and Adams stated that the right aortic arch with mirror image branching was found in 47% of the specimens [20]. Sprong and Cutler classified the right aortic arches into 2 groups and reported 13 cases of the right aortic arch with mirror image branching [26]. Laura Knight et al reported (84.5%) the right aortic arch with mirror image branching according to the origin of the branches from the aortic arch [27]. R.A.

Chiron et al in their study showed that 18 cases were of the right aortic arch with the mirror image branching pattern [28]. The right aortic arch with mirror image branching pattern was compared with that reported by previous authors.

The left and the right aortic arch refer as to which bronchus is crossed by the arch and not to the side to which the aortic arch ascends.

The above said arch is the left-right mirror of a normal left aortic arch. Laura Knight et al reported that the right aortic arch without the retro oesophageal aortic segment and with mirror image branching occurs in 84.5% of the specimens [27]. The right aortic arch which was encountered in my study had no retro esophageal aortic segment. The right sided arch of the aorta is characteristic of that found in birds.

#### **CLINICAL IMPORTANCE:**

##### **a) Common Sharing For the Brachiocephalic and the Left Common Carotid Artery**

This variant is of no consequence, although some have suggested that the innominate (brachiocephalic) artery causing compression of the trachea is more frequent when a common trunk is present. Tracheal pressure may be present even if the artery arises a little further to the left on the aortic arch than in its normal position. In this situation, any vascular trauma may have fatal consequences.

##### **b) The Left vertebral artery arising from the aortic arch**

This variant is important only in that it should not be confused angiographically or echocardiographically with the anomalous right subclavian artery in which there also are four vessels from the arch of the aorta.

The distinguishing feature here is the normal appearance of the right innominate (brachiocephalic) artery being larger than the

second (left carotid) and the third (left vertebral) being smaller than the fourth (left subclavian). There is no functional significance about this variant.

##### **c) The Right Subclavian Arising As the 4<sup>th</sup> Branch From the Aortic Arch:**

This is the most common arch anomaly occurring in 0.5% of the general population. The incidence of this variant is high at 38% in Down's syndrome patients with congenital heart disease. In this variation, there is no innominate (brachiocephalic) artery and the first and second branches (the right and left carotid arteries) tend to be similar in size.

#### **CONCLUSION:**

From the results of our present study, we conclude that no specific south Indian variation beyond the limits of average fluctuation was noted and also, the variations are not only clinically important, but are also clinically important to both the patient as well as the operating surgeons.

#### **REFERENCES:**

- [1] Liechty, Shields, Anson. Northwestern Univ. Med. School. Variations of branches of aortic arches - from Anson and Mc.vay, Surgical Anatomy, 1957; Vol.I: 427 - 429.
- [2] Anson(1963 )cited in Gray's Anatomy, Anatomical Basis of Medicine and Surgery, 38th edition, Churchill Livingstone, London, 1995.1512-1513.
- [3] N.L. Wright. Dissection study and mensuration of the human aortic arch. Journal of Anatomy. 1969; 104 (2): 377-385.
- [4] Bertolini A, Pelizza A et al. Vascular rings and slings, Journal of Cardiovascular Surgery (torino). 1987; 28 (3) : 301 - 312.
- [5] Gross, R.E. Arterial malformations which cause compression of the trachea or esophagus. Circulation. 1955; 11:124-134.
- [6] Gross R.E., Ware P.F. The surgical significance of aortic arch anomalies. Surg. Gynec. and Obst. Journal. 1946; 83: 435-448.
- [7] Neuhauser E. The roentgen diagnosis of double aortic arch and the other anomalies of great

- vessels. American Journal of Roentgenology. 1946; 56: 1-12.
- [8] Edwards J E. Anomalies of the derivatives of the aortic arch system; Med. Clini. North America: 32; 925-949.
- [9] Geddes A C. Note on the reputed passage of abnormal right subclavian artery (a) in front of the trachea, (b) between the trachea and oesophagus. Journal of Anatomy and Physiology. 1911; 45: 199-201.
- [10] Gladstone R.J and Wakeley C.P.G. Two cases, considered from the developmental standpoint, in which the right subclavian artery arose from the arch of the aorta beyond the origin of the left subclavian artery; with a note on the relation of the subclavian veins to the cardinal system Journal of Anatomy and Physiology. 1915; 49: 362-374.
- [11] Daseler E H. and Anson. surgical anatomy of subclavian artery and its branches. Surg. Gynaec. and Obst. 1959; 108: 149-174.
- [12] Holzapfel G. Ungewöhnlicher Ursprung und Verlauf der Arteria Subclavian. Anat. Heft. 1899; 12: 373 - 523.
- [13] Satyapal K.S, Singaram - University of Natal, Aortic arch branches variations - case report and arteriographic analysis. South African Journal of Surgery. 2003; 41(2): 48-50.
- [14] Martia L. Nelson, Chad D. Sparks - unusual aortic arch variations: distal origin of common carotid arteries in Japanese population. Clinical Anatomy. 2001; 14 (1): 62 - 65.
- [15] Morris human anatomy - 12th edition. the blakiston division, Mcgraw- Hill book company, New yor1997;673-679
- [16] Hollinshead W H. Anatomy for surgeons. 1954; Vol. I; 468. London
- [17] Piersol G A. Human anatomy 6th ed. Philadelphia and London: JB, Lippincott Company. 1906; 726.
- [18] Rutherford. Textbook of vascular surgery - Vol II chapter 115 - Anatomy and angiographic diagnosis of extracranial and intracranial vascular disease, Larry - Stuart deutsch. W B Saunders Company. 1481 - 1493.
- [19] Brodie G. Rare abnormality of the aortic arch. Lancet. 1888; 2: 971.
- [20] Moss and Adams, Paul M. Weinberg. Lippincott's Williams & Wilkins. Vol. II; 707-735.;
- [21] Lemke et al. 1999 cited in case report - bilateral arch origin of the vertebral arteries, American Journal of Neuroradiology 23, March 2000 : 455 - 458.
- [22] Sait albayram, Philippee Gailloud and Bruce A. Wasserman - bilateral arch origin of the vertebral arteries. American Journal of Neuroradiology . 2002; 23:455 - 458.
- [23] Gray's anatomy 39th edition. The Anatomical Basis of Clinical Practice, Elsevier Churchill Livingstone., 1022-1023.
- [24] V.Almenar - Garcia, F. Terol, J. Correa - Lacarcel. Retro-oesophageal subclavian artery. Surgical and Radiological anatomy. 2002; 24: 231-234.
- [25] Saeed M.Rufai AA. Variations in the subclavian axillary arterial system. Saudi Medical Journal. 2002; 23 (2): 206 - 212.
- [26] Sprong David H JR and Norman L Cutler. A case of human right aorta. Anatomical Records. 1930; 45: 365 - 375.
- [27] Laura Knight, Edwards JE. Right aortic arch types and associated cardiac anomalies. Circulation. 1974; 50: 1047-1051.
- [28] R.A. Chiron, Z. Rotstein. Anomalies of the fetal aortic arch: a novel sonographic approach to in-utero diagnosis. Ultrasound in obstetrics and gynecology. 2002; 20 (6): 553.
- [29] Young Shin, Yong-Gu Chung et.al. Amorphometric study on cadaveric aortic arch and its major branches in 25 Korean adults :The perspective of endovascular surgery. J. Korean Neurosurg Soc;78-83 2003
- [30] N.Z.Makhanye et.al Variations of left aortic arch branches, South African Journal of Radiology 2004;567-569
- [31] Toshiyuki Saito, Yoshiki Tamatsukur et.al. Three cases of retro-oesophageal right subclavian artery. J.Nippon Med.School.2005:7216.
- [32] Gupta M.Sodhi L. Variations in branching pattern, shape, size and relative distances of arteries arising from arch of aorta. Nepal Med.Coll.J.2005 June7(1);13-17
- [33] Koh-ichi Yamaki et.al. Anatomical study of vertebral artery in Japanese adults. Anatomical Science International 2006, Vol 81, No(2) 100-106.
- [34] Kazuchika Suzuki et al. Total aortic arch replacement with arch vessel anomalies. Am.Thoracic.Surg 2006.81:2079-2083.
- [35] Soubhagya. R. Nayak et al. Anatomical organization of aortic arch variations in India: Embryological basis and review. J.Vasc.Bras.Vol 5 No.2 Porto Alegre, June 2006;878-890
- [36] Suresh et.al. Variations in branching pattern of aortic arch in three Trinidadians, West Indian Med.J.2006, vol55(5):1
- [37] Jin-Tae Kim et.al. The carina as a useful radiographic landmark for positioning the intraaortic balloon pump. Anaesthesia and Analgesia, 2007 Vol 105. N:3, 735-738.
- [38] Konstantinos.I.ET.AL. Study of aortic arch in 633 angiographies; Clinical significance and literature review. Surgery.Rad.Anatomy Vol31, No.5 2009:319-323
- [39] Berko Nekanel et.al. Variants and anomalies of thoracic vasculature on computed tomographic angiography in adults reviewed in 1000 CT Angiograms. Journal of Computed Assisted Tomography. July/August 2009-Vol.33-Issue 4:523-528.

- [40] G.G.Jakanani,W.Adiar,Frequency of variations in aortic arch anomaly depicted on multidetector CT .Clinical Radiology.Vol 65, Issue 6:481-487.
- [41] Budhiraja Virendra.Aortic arch variations:Embryological basis and surgical correlation.Indian Journal of Forensic Medicine and Toxicology 2010,Vol 4.Issue-1.
- [42] Marios Loukas et.al Retro-oesophageal right subclavian artery originating from left aortic arch-a case report and review of literature, Folia,Morph, Vol 63,No:1 141-145.